Microaneurysms Detection in Retinal Fundus Images

Sathananthavathi.V, Indumathi.G

Abstract: Diabetic retinopathy (DR) is accepted to be the vision threatening disease in most of the developing countries. The anomalies caused by Diabetic retinopathy are identified through Micro aneurysms and Hemorrhages. Manual detection of abnormalities like Micro aneurysm and Hemorrhages in color fundus images is a time consuming process and hence there is a need of an automated system to grade the level of diabetic retinopathy. The proposed method is based on profile based features, local features and SVM classifier to detect microaneurysm in retinal fundus image. The microaneurysm detection accuracy of the proposed method is about 93.73% using SVM classifier and 90.71% for KNN classifier.

Keywords: Fundus images, Intensity profile analysis, Red lesions, Microaneurysm, Diabetic Retinopathy

I. INTRODUCTION

Diabetes is the most commonly seen disease which affects the retina in human eye. If it is not diagnosed earlier and left untreated, it may lead to loss of sight. One in three patients has the symptoms of diabetic retinopathy; also one out of ten persons is at the vision threatening stage. In India [1], nearly 90 million people are affected by diabetic disease. Diabetic retinopathy is the highly developed form of the disease. Diabetic retinopathy is considered as an advanced level and diagnosed through symptoms like Red lesions and bright lesions. Microaneurysms (MA) and hemorrhages are red lesions usually noticed at the early stages named mild non proliferative DR and in moderate non proliferative DR, bright lesions like exudates and cotton wool spots are also identified along with red lesions. These abnormalities are considered to be major facts in the grading of DR severity. Existence of numerous microaneurysms is the earliest indication of DR [2]. Due to microaneurysms the blood vessels narrowed and in some cases it blocks the flow of blood in the retina blood vessels. At later, these microaneurysms may burst, and lead to the condition called hemorrhage. Although microaneurysms are the initial signs of Diabetic retinopathy, hemorrages are also helpful for screening and beneficial for grading task. At the severe level of disease progression, vessels may get thickened and due to the inability to supply nutrients to the retina, fragile blood vessel [3] will form. In this stage, blood vessels seem to be twisted and tortuous. The changes in the blood vessel pattern also considered for diagnosis purpose. Among these abnormalities microaneurysms are said to be the earliest one and it is still challenging to identify in fundus images. In this work, the detection of microaneurysms is proposed based on shape and profile features.Accuracy, sensitivity and specificity are considered as the performance measures for the proposed work.

II. RELATED WORK

Detection of microaneurysm in the presence of retinal blood vessels is still a challenging task. Many MA detection and segmentation methodologies are already proposed but still the challenge is alive. Morphological operation [4-5] is applied to remove the vascular patterns, with linear structuring elements at different orientations. Elements which are smaller than the structuring elements, like microaneurysms and in some cases Hemorrhages are eliminated by this operation. Hence top hat transformation of this will detect the candidate regions. Different template matching methods are also proposed for microaneurysm detection. A local template matching in wavelet domain has been used for MA detection. Wavelet sub-bands based template matching [6] is applied for the detection of micro aneurysm. The wavelet transform with lifting scheme framework is used in training phase and the location of micro aneurysms is detected on the matching result using threshold. In view of the fact that, retinal fundus images are likely to have variation in illumination and shades, preprocessing [7-11] is essential in the detection process to enhance the image quality. A Gaussian matching filter [7], was applied on the morphological bilinear top-hat transformation in order to enhance abnormal regions like MA, and MA candidates are segmented using a recursive region growing method. Since vessel region also identified as the candidate region, supervised learning is implemented to eliminate the false candidates. In [12], a multi scale Gaussian correlation coefficients based method is proposed and the MA candidate is identified using the maximum correlation coefficient by the different Gaussian Kernels for each pixel. In [13], a hybrid method includes morphological top hat transform and classification by K NN classifier is proposed for MA detection. In [14],MA detection is proposed by combining Gaussian mixture model and logistic regression classification. Dictionary learning along with sparse representation lassification [15] is proposed to detect MAs.

Revised Manuscript Received on March 25, 2019.
Sathananthavathi.V,Department of ECE,Mepco schlenk Engineering college, sivakasi

Indumathi.G,Department of ECE,Mepco schlenk Engineering college, sivakasi

They also utilized the Gaussian Correlation coefficients to identify the true candidates among spurious candidates and a separate dictionary was learned for each case. Microanuerysms and Hemorrhages are identified by dark pixel regions [16-17] in most of the regions and the vessels are subtracted to extract only the abnormal regions. But the drawback of this method is due to the false positives in vessel segmentation may lead to unrecoverable loss of lesion regions. Shape feature based MA detection is also proposed in several methodologies. In [18], a new set of shape features is intended to detect MA, hence the methodology do not involved with segmentation of candidate regions. Each minimal area is considered as a candidate and shape features are extracted through morphological flooding operation. In the case of a lesion, the local minimum region indicates the principal location from which the blood is leaking gradually, in a more or less isotropic manner, depending on whether the lesion is an MA or an HE. In addition several other methods like bottom hat transformation [19], circular hough transform [20], Radon transform [21], local contrast normalization based method [22], and also neural network classification for MA detection [23] , Convolutional neural network based detection [24] are also proposed.

III. PROPOSED TECHNOLOGY

The proposed method for the microaneurysm abnormalities detection in fundus images are based on intensity profile features and shape features. The proposed work starts with the preprocessing operation to make the microaneurysm region clearly compared to the background. The candidate region is identified from the preprocessed image, 22 discriminant features are extracted from that region and finally classified. Figure 1 depicts the proposed workflow.

Pre-Processing

The retinal images are usually have non uniform illumination. Due to the non uniform illumination, the microaneurysms present in the low bright and poor contrast regions are difficult to detect through screening process [25]. *Illumination Equalization*: The green channel of the image is inverted and it is considered as the background images. A mean filter of size 53 × 53 is applied to estimate the illumination. Shade variation is corrected by subtracting the back ground image from the original fundus image. The average intensity of Inverted green channel is added to maintain the same gray range as in the inverted green channel of the image and it is specified by the following equation: (1) where I-Original Image, m- green channel mean, Ibg - Back ground Image. Contrast Limited Adaptive Histogram Equalization & Smoothing: Even in the illumination equalised image some of the microaneurysms are not still identifiable. To sharpen the details in the low contrast region, Contrast limited adaptive histogram equalization (CLAHE) is applied. Finally smoothing is done with the help of Gaussian filtering process. Figure 2 shows the preprocessed outputs.

$$Ie = I - I_{bg} + m$$

A. Candidate Extraction

Candidate Detection plays a vital role in Abnormalities detection in retinal fundus images. Using this method unwanted regions other than the abnormalities are ignored. The candidate regions are identified by taking profile of the region along different directions with the predefined conditions. If the region is the candidate region, then it atleast have one maximum due to the fact that microaneurysms appear as the bright pixel. To overcome the false identification of noise region as candidate region, maxima values at different orientation is observed.

Peak Detection & Thresholding: Peak Detection is the first step to find out the Abnormality region using intensity profile Analysis. To detect the intensity profile, the whole image is separated into small patches and intensity profile is obtained. 20 Line detectors of different orientations with nine degree spacing are constructed for each of the locally maximum pixel to study the surrounding. The local maximum pixel of the profile is the center pixel. If in any profile when the absolute difference between consecutive pixels larger than 5 is observed, then that candidate is excluded. From the remaining candidate, starting and ending position of increased intensity level and decreased intensity level is taken. Thresholding level of patches are taken as the maximum intensity of profile. To reduce false selection of candidate patches, ratio of the candidate region to

circumcircle region (Eq. 2) is calculated. If the ratio is less than 0.5 means that patches are discarded.

B. Feature Extraction

Local Features: Hessian based matrix is used to find out the features of candidate patches. Features are taken by the second order partial derivatives of each pixel of patches.

$$H_{xx} = \begin{bmatrix} Dxx & Dxy \\ Dxy & Dyy \end{bmatrix}$$

Where,

$$D_{xx} = G_{xx}(x, y : \sigma * I(x, y))$$
$$D_{xy} = G_{xy}(x, y : \sigma * I(x, y))$$
$$D_{yy} = G_{yy}(x, y : \sigma * I(x, y)) \quad (2)$$

The eigen values relation of the Hessian matrix is used for the finding of various structures. λ_1 and λ_2 are the eigen values. The probability map for the small round object is given by the following relation:

$$P(x,y:\sigma)=\begin{cases}0 & ,\lambda_1>0 \;||\; \lambda_2>1\\ \frac{2}{\pi}\tan\left(\frac{|\lambda_2|+|\lambda_1|}{|\lambda_2|-|\lambda_1|}\right) & ,\ \lambda_1\neq\lambda_2\\ 1 & ,\lambda_1=\lambda_2<0\end{cases} \quad (3)$$

P(x,y) is the maximum of P(x,y,σ). Mean, Standard deviation and maximum of Pmax, |H| is extracted as features, where $|H|=\lambda_1 Max \times \lambda_2 Max$.

Intensity and shape features: Shape features [14] and [15] like area, symmetry and aspect ratio are extracted from the selected candidate region. Area is the number of pixels in the candidate region. Symmetry of the candidate region is calculated using $R=\frac{\sum_{i\in\omega}\sqrt{(d_j-\bar{d}}}{N}$ (4) Here dj is the space from an edge pixel to the centre pixel of the candidate region. The $\bar{d}$ is the average distance and N is the number of pixels. The aspect ratio is the length of the major and the second major eigen value of the covariance matrix of the candidate region. The average contrast of edge pixels is given by

$$M_c=\frac{\sum_{i\in 1} g_1}{N_1}-\frac{\sum_{i\in 2} g_2}{N_2} \quad (5)$$

where the category 1 is a group of pixels which belong to the eight neighboring pixels of the center pixel and their pixel intensity is larger or equal to that pixel. N1 is the number of pixels in

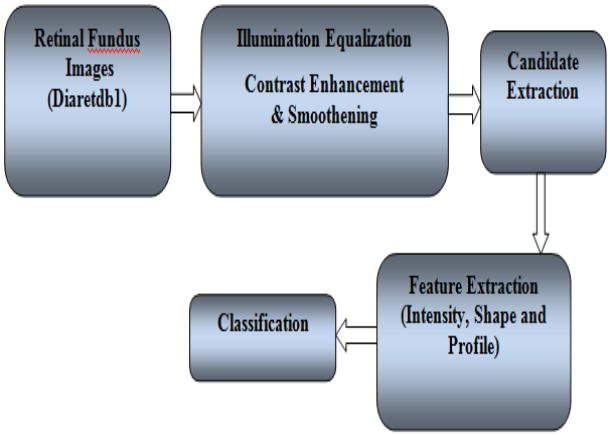

Fig.1 Proposed Method

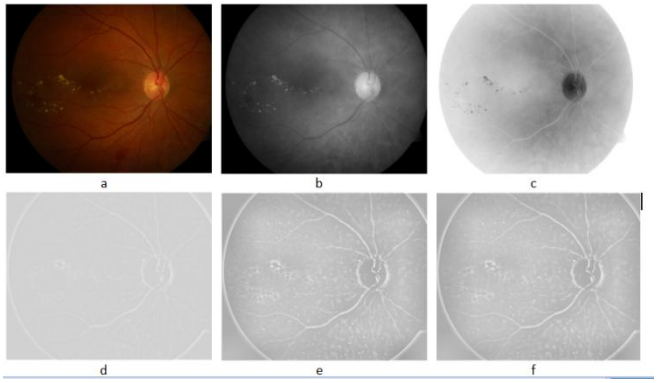

Fig. 2 Pre-processed Output

a- input image; b-Green Channel; c-Inverted Green Channel; d-illumination equalization; e- contrast equalization; f-smoothing

Table 1. Accuracy Measurement.

	Image number									
	005	007	008	009	010	011	012	013	014	015
Number of MA	16	19	24	22	33	31	19	25	21	26
SVM	93.2	89.3	91.6	95.4	96.9	96.7	94.7	92	95.2	92.3
KNN	93.2	84.2	87.5	90.9	93.9	93.5	89.2	92	90.4	62.3

Table 2. Comparison

Year	Method	Sensitivity
2015	Bottom-hat transform combined with PCA	92.3%
2015	Circular Hough transform combined with KNN	87.5%
2013	Radon transform combined with SVM	89.5%
2006	local contrast normalization	63.7%
2010	Neural network based classification	86.0%
2017	Proposed method	95.6%

first category. Category 2 is the remaining pixels of 8-neighboring pixel. The standard deviation of contrast of edge pixels is given by

$$\sigma_{edge}=\frac{\sum_{i\in edge}\sqrt{(c_i-c)^2}}{N_{edge}} \quad (6)$$

where edge is a group of edge pixels and Nedge is the amount of edge pixels. The average intensity & Standard deviation of microaneurysms candidate region is

Published By:
Blue Eyes Intelligence Engineering
& Sciences Publication

$$\mu_{candidate} = \frac{\sum_{i \in candidate} n_i}{N_{candidate}} \quad ;$$

$$\sigma_{candidate} = \frac{\sum_{i \in candidate} \sqrt{(n_i - \mu_{candidate})^2}}{N_{candidate}} \qquad (7)$$

The mean intensity & standard deviation of background is calculated similar like that of Eq.(7). The difference among the average intensity of microaneurysm candidate and its background is given by

$$\mu_{diff} = \mu_{candidate} - \mu_{background} \qquad (8)$$

The difference among the maximal intensity of candidate region and a local contrast is $Diff = n_{\max} - u$ where

$$u = \mu_{background} - 0.53\sigma_{background} \qquad (9)$$

Profile Features: Profile features [26] are taken from the intensity profile of each selected candidate patches. The peak width is the difference between the start and end of the peak is given by wpeak =D Re - I Rs. The increasing ramp height is given by Hir =p[I Re] - p [I Rs] . The decreasing ramp height is Hdr = p[Drs] - p [Dre]. The average height of the peak is Hpeak = p[i] /wpeak. The start of increasing ramp height is Hirs = p [IRs]. The termination of the decreasing ramp height is HDre = p [D Re].

IV. EXPERIMENTAL RESULTS

The Diaretdb1 and DRIVE databases are the freely available images for estimating the methods of microanuerysm detection. Diaretdb1[3] comprises 28 training images & 61 testing images. Among the testing images, 10 images with symptoms of all stages of DR are selected and used. The proposed method of MA detection based on the Intensity & shape features. Totally 22 features are extracted from both Diaretdb1 and DRIVE databases. Among the 22 features, 6 features are profile features and 18 features are shape based features. These 22 features are utilized to differentiate the abnormal region from normal regions in the fundus images using SVM and K NN classification. Both the algorithms meant for its simplicity and also they are highly efficient to get better classifier accuracy, hence in this work these classifiers are selected for classification. The proposed work of abnormality detection is initiated by separating the images into patches of size of 50x50 to identify the anomaly section in the image. SVM classifier and KNN classifier is trained with the Intensity and shape features derived from 28 images of Diaretdb1. The classification accuracy is measured as the performance measure for the proposed method and it is the ratio of sum of true positive patches and true negative patches to the total number of patches tested. Table 1 displays the accuracy measurement of proposed methodology. To measure the performance of proposed methodology, the abnormal patches are initially labelled manually and it was compared with the obtained classification result. Table 2. lists some of the existing methodology for MA detection on Diaretdb01 database. Accurate localization of the MAs is essential for the diagnosis, it is being depends on the performance of the classifier which is evaluated using Receiver Operating Characteristics (ROC).

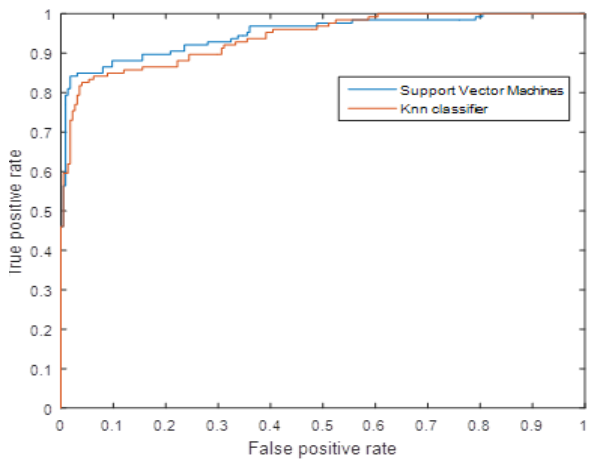

Fig 3. ROC plot

Area under Curve (AUC) value for SVM is 93.73% and for KNN it is 90.71% for the same training samples shown in Figure 3. Sensitivity is the measure which describes how well the abnormal region is identified as the abnormal region. Sensitivity of proposed work using SVM and K NN is 95.6% and 95.14% respectively. Performance of the proposed method by SVM classifier in terms of accuracy is superior compared to K NN classifier. Some normal image regions with thin vessel segments and uneven contrast regions are recognized as anomalous regions. It is due to the same range of intensity for vessels and anomalous regions.

V. CONCLUSION

Microaneurysm is the indicator of early sign of vision damage due to Diabetic retinopathy. In this work, presence of microaneurysms in retinal fundus images are identified by means of profile based intensity features & shape features. Accuracy achieved by the proposed work using SVM classifier is about 93.73% and using KNN classifier is about 90.71% for diartedb1 database. The methodology can also be extended for the detection of other abnormal conditions due to DR like haemorrhages and their augmentation with respect to time for grading the disease progression based on the measurement.

REFERENCES

1. H.R.Taylor, J.E.Keeffe, World blindness: A 21st century perspective, British J. Ophthalmology, 85 (2001), 261–266.
2. G.Quellec, M.Lamard, P.M.Josselin, G.Cazuguel, Cochener, C.Roux, Optimal wavelet transf,rm for the detection of microaneurysms in retina photographs, IEEE Trans. Med. Imag, 27 (2008), 1230–1241.
3. M.Mizutani, T.S.Kern, M.Lorenzi, Accelerated death of retinal microvascular cells in human and experimental diabetic retinopathy, J.Clinical Investigation, 97 (1996), 2883.

4. B.Lay, Analyse automatique des images angiofluorographiques au cours de la retinopathie diabetique. Ph.D. dissertation, Centre of Mathematical Morphology, Paris School of Mines, Paris, France,(1983).
5. C.E.Baudoin, B.J.Lay, J.C.Klein, Automatic detection of microaneurysms in diabetic fluorescein angiographies, Rev. Epidemiol Sante Publique, 32 (1984), 254–261.
6. G.Quellec, M.Lamard, P.M.Josselin, G.Cazuguel, B.Cochener, C.Roux, Optimal wavelet transform for the detection of micro aneurysms in retina photographs, IEEE Transactions On Medical Imaging, 27 (2008), 1230–1241.
7. T.Spencer, J.A.Olson, K.C.McHardy, P.F.Sharp, J.V.Forrester, An image-processing strategy for the segmentation and quantification of microaneurysms in fluorescein angiograms of the ocular fundus, Comput. Biomed. Res. , 29 (1996) 284–302.
8. M.J.Cree, J.A.Olson,K.C.Sharp, J.V.Forrester, A fully automated comparative microaneurysm digital detection system, Eye, 11(1997), 622-628.
9. A.J.Frame, P.E.Undrill, M.J.Cree, J.A.Olson, K.C.Sharp, J.Forrester, A comparison of computer based classification methods applied to the detection of microaneurysms in ophthalmic fluorescein angiograms, Computer Biological medi, 28(1998), 225-238.
10. A.Mandonca, A.Campilho, J.Nunes, Automatic segmentation of microaneurysms in retinal angiograms of diabetic patients, Proceeding international conf image anal. Process (1997), 728-733.
11. A.D.Fleming, S.Philip, K.A.Goatman, Automated microaneurysm detection using local contrast normalization and local vessel detection, IEEE Trans. Med. Imag, 25 (2006), 1223–1232.
12. B. Zhang, X.Wu, J.You, Q.Li, F.Karray, Detection of microaneurysms using multi-scale correlation coefficients, Pattern Recognition, 43(2010) 2237-2248.
13. M.Niemeijer, B.V.Ginneken, J.Staal, M.S.A.Suttorp-Schulten, M.D.Abramoff, Automatic detection of red lesions in digital color fundus photographs, IEEE Trans. Med. Imag, 24 (2005), 584-592.
14. C.I.Sanchez, R.A.Hornero, Mayo, M.Garcia, Mixture model-based clustering and logistic regression for automatic detection of microaneurysms in retinal images, Proc. SPIE, 7260(2009), 72601M-1-72601M-8.
15. B.Zhang, F.Karray, Q.Li, L.Zhang, Sparse representation classifier for microaneurysm detection and retinal blood vessel extraction, Inf. Sci., 200 (2012), 78-90.
16. C.Sinthanayothin e*t al*, Automated detection of diabetic retinopathy on digital fundus images, Diabetic Med. A J. Brit. Diabetic Assoc., 19(2002), 105–112.
17. S.Ravishankar, A.Jain, A.Mittal, Automated feature extraction for early detection of diabetic retinopathy in fundus images, In Proc IEEE Conf. Comput. Vis. Pattern Recognit., (2009), pp. 210–7.
18. Lama Seoud, Thomas Hurtut, Jihed Chelbi, Farida Cheriet, J.M.Pierre Langlois, Red Lesion Detection Using Dynamic Shape Features for Diabetic Retinopathy Screening, IEEE Transactions On Medical Imaging, 35(2016), 1116-1126.
19. R.R.Roberto, M.C.Jorge, H.C.Jonathan, J.U.V.Laura, A method to assist inthe diagnosis of early diabetic retinopathy: Image processing applied to detection of microaneurysms in fundus images, Computerized Medical Imaging Graphics, 44(2015), 41–53.
20. S.S.Rahim, C.Jayne, V.Palade, J.Shuttleworth, Automatic detection of microaneurysms in colour fundus images for diabetic retinopathy screening, Neural Computing Appl, 44(2015), 1–16.
21. J.Oliveira, G.Minas, C.Silva, Automatic detection of microaneurysm based on the slant stacking, IEEE 26th International Symposium on Computer-Based Medical Systems (CBMS), (2013) pp. 308–313.
22. A.D.Fleming, S.Philip, K.A.Goatman, J.A.Olson, P.F.Sharp, Automated microaneurysm detection using local contrast normalization and local vessel detection, IEEE Trans. Med. Imaging, 25(2006), 1223–1232.
23. M.Garcia, M.I.Lopez, D.Alvarez, R.Hornero, Assessment of four neural network based classifiers to automatically detect red lesions in retinal images, Medical Engineering & Physics, 32(2010), 1085–1093.
24. Jen hong tan, Hamido fujita, Sobha sivaprasad, Sulatha V Bhandary, Krishna rao, Kuang Chua, Rajendra Acharya, Automated segmentation of exudates, Haemorrhages, Microaneurysms using single convolutional neural network, Information Sciences, (2017), doi: 10.10 16/j.ins 2017.08.050
25. Niemeijer, B.van Ginneken, M.Cree, A.Mizutani, Retinopathy online challenge: Automatic detection of microaneurysms in digital color fundus photographs, IEEE Transactions On Medical Imaging, (2010).
26. [26] Istvan Lazar, Andras Hajdu, Retinal Microaneurysm Detection Through Local Rotating Cross-Section Profile Analysis, IEEE Transactions on Medical Imaging, 32, (2013),400 - 407.

Published By:
Blue Eyes Intelligence Engineering
& Sciences Publication