International Journal of Recent Technology and Engineering (IJRTE)
ISSN: 2277-3878 (Online), Volume-7 Issue-4s, November 2018

Mathematical Morphology for Recognition of Hard Exudates from Diabetic Retinopathy Images

R. Sathish Kumar, R. Karthikamani, S. Vinodhini

Abstract: ***Diabetic retinopathy is the most frequent form of diabetic eye disease. It will typically affects people who have diabetes for a significant number of years. Retinopathy becomes particularly dangerous because it will affect all diabetics and, increases the risk of blindness, when it is left untreated.To avoid total loss of sight the ophthalmologist will treat the patients by sophisticated laser treatment,if detected effectively at an initial period. One of the main symptoms of initial stage of diabetic retinopathy is analysis of Hard exudates. At the early stage, using mathematical morphology the exudates are identified and removed.***

Keywords: ***Diabetic retinopathy, Mathematical morphology, Fuzzy logic.***

I. INTRODUCTION

In a human eye Retina is the inner memberane. Diseases that take location inside the retina affect our eye-sight immediately. Hypertension and diabetes mellitus are systemic illnesses in eye which cause a few pathological adjustments. We can give pathological facts using virtual pics of the fundus eye. Diabetic retinopathy, also referred to as as diabetic eye ailment, is a scientific situation wherein harm happens to the retina due to diabetes and is a essential motive of blindness. The people who have had diabetes for 20 years or more might be easily affected. Eighty percent of humans have been stricken by diabetes. When the modifications in blood glucose tiers cause modifications in retinal blood vessels will produce Diabetic retinopathy. In some cases, these vessels will swell up and leak fluid into the rear of the eye. The early ranges of diabetic retinopathy can also occur without symptoms and without pain. A real impact at the vision will now not arise until the sickness advances [1].

The characteristics of Diabetic retinopathy is defined by increase of retinal microaneurysm, haemorrhages and exudates. Microaneurysms are crucial dilatations of retinal capillaries and it looks like a small spherical darkish red dots. Next we must differentiate haemorrhages and exudates. When the blood leaks from retinal vessels then it said to be haemorrhages, exudates are identified when lipid or fats leaks from aneurysms

. Based on the illess of the patient the value of aneurysms, haemorrhages and exudates varied. Depending upon this values we can identify the exudates from retinal images.

To detect this disorder lot of techniques are available.RRGS technique is used to detect the darkish red dots , leakage of blood from retinal vessels and fats leaks from blood vessels. The detection of vessels can be done by neural approach. Microaneurysms and haemorrhages are detected with the use of pixel type approach and features are classified using neighbour classifier [2].

In DR detection there are many techniques available.At initial disease stage Herehard exudates are detected from retinal images [4].

There are many research specializing in hard exudates with numerous techniques and strategies in automatic retina evaluation.Using Logistic regression HEs and the retinal history areas are efficiently picked out and HEs are detected automatically.the image processing techniques like mediam filtering , image thresholding strategies have been used for detecting HEs. by using related information in retinal images we can detect HEs. The context was defined by excessive-stage contextual-based totally features based on the spatial relation with neighbouring anatomical landmarks and comparable lesions. HEs have been segmented, the use of mathematical morphology after which reaching capabilities. Afterwards, these features had been labelled by using the guide vector machine.[5]

Chen et al supplied a unique approach to mechanically hit upon HEs in coloration retinal images.By combining histogram segmentation with morphological reconstructionHE regions are extracted. Next, they described forty four great capabilities for each candidate location. To categorise the candidate regions for HEs aSSV gadget is in the end trained primarily based on these features used [6], based on the morphological operation, the retinal imagesare pre-processed and optic disc and the blood vessels identified. In pre-processing the hard exudates from retinal colour images are segmented.Hard exudates are identified with the help of logistic regression.The extracted set of functions used to differentiate hard exudates and inheritance.DLM method is used to detect HEs and variance calculation method proposed [7].

Ranamuka and Meegama [8] introduced morphological processing and fuzzy logic. Using the two techniques hard exudates is detected.

At the initial degree, the HEs are recognized using mathematical morphology.

Manuscript published on 30 November 2018.
*****Correspondence Author(s)
Dr. R. Sathish Kumar, Asst. Professor (Sr. G), Dept. of mathematics Bannari Amman Institute of Technology, Sathyamangalam, Erode(Dt), Tamil Nadu, India
Mrs. R. Karthikamani, Asst. Professor, Dept. of EIE, Bannari Amman Institute of Technology, Sathyamangalam, Erode(Dt), Tamil Nadu, India
Ms. S. Vinodhini, Asst. Professor, Dept. of EIE, Bannari Amman Institute of Technology, Sathyamangalam, Erode (Dt), Tamil Nadu, India

From adaptive fuzzy logic algorithm the hard exudates are extracted. The values will be obtained from RGB color space of retinal for f sets and e bershi functions.Xu and Luo [8].In this approach MDD classifier is used to identify the HES.Digital records may be typically utilized to help the practionerin healthcare studies for analysis. To detect optical discgabor filter kernels used.Watersheed Segmentation and thresholdingstrategies are used to find the HEs and SVM classifier is used for classifying exudates.[9,10,11]

II. THE PROPOSED METHODOLOGY

The set of rules planned hereis the use of the standards of mathematical morphology techniques and fuzzy common sense to detect hard exudates in DR.In first stage three different process must be carried out and in second stage fuzzy logic is applied to detect the HEs which is follows in Fig 3.1.

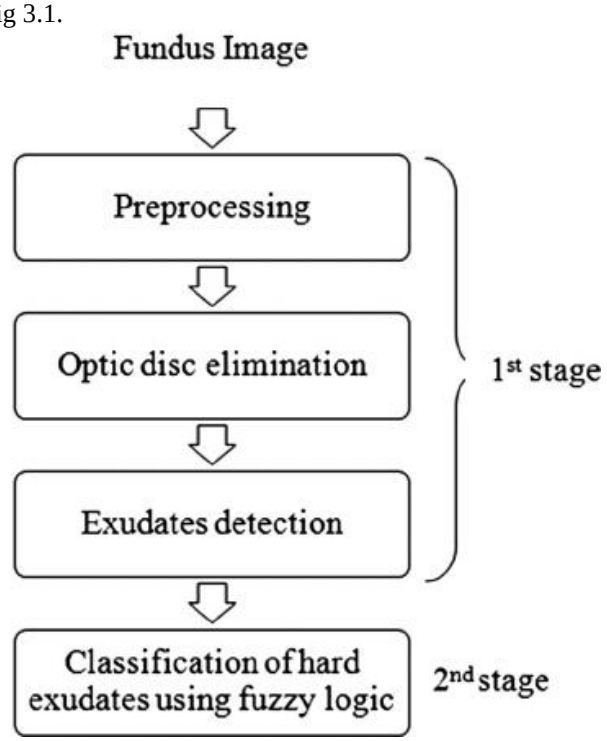

Fig.3.1

In the pre-processed image closing operator is used with flat disc shape.Initially,gray scale image is obtained from original image. Fig 3.2 shows the original image and converted image. Then,the median filter is used for noise suppression. Fig 3.3 indicates the intensity channelof the original imageand median filtered image.Subsequently, the assessment restrained adaptive histogram equalization became implemented for contrast images. Then it is binarised the use of a thresholding approach. For additional processing the colour image is converted to gray scale image.Use of fuzzy logic the hard exudates are classified in second stage.From the RGB colour images the fuzzy units are derived.Fuzzy policies are applied to find out the existence of HES in DR images.

A.First Stage of Processing:

In preprocessing the RGB space of the real image was converted to HSI space. To separate the intensity component from color component HSI transformation is used.Contrast-limited adaptive histogram equalization (CLAHE) was applied for contrastenhancement. Filtering operation is used for noise reduction

B. Optical Disc Removal

At first, the original image is preprocessed. Closing operator with flat disc shape structureis used for preprocessing and with the help of thresholding technique the resultant image is binarised. The newly converted image is Ω (binary image)

$$\Omega = \bigcup_{k \epsilon m} C_k,\ C_i \bigcap C_j = 0, \quad \forall i, j \epsilon m,\ i \neq j$$

Where m = 1, 2,…, k
k is the no of connected components. The compactness C of Ri is measured by

$$C(R_i) = 4\pi \frac{A(R_i)}{P^2(R_i)}$$

HereA(Ri) is the no of pixels in i^{th} region and P(Ri) is the no of pixels around Ri.

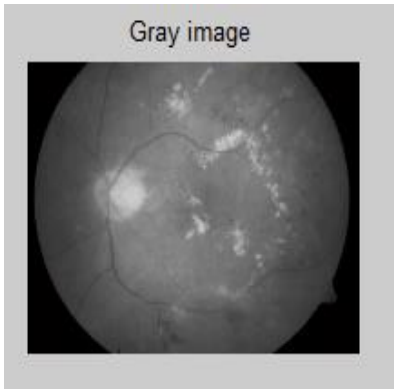

Fig.3.2 Original and Gray Scale Image

Published By:
Blue Eyes Intelligence Engineering
and Sciences Publication (BEIESP)

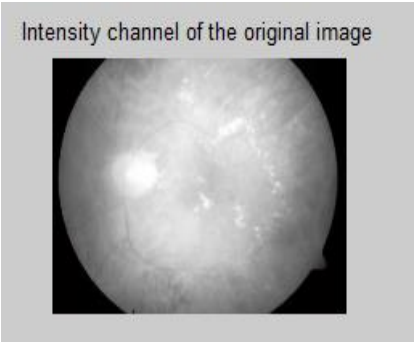

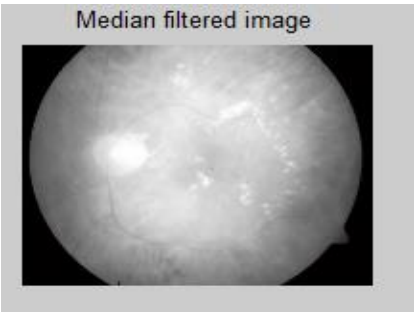

Fig.3.3 Intensity Channel of the Original Image and Median Filtered Image

Fig.3.4 Histogram Equalized Image

C. Recognition of Exudates

The subsequent step is to identify exudates from the original image. Before applying a threshold technique the high contrast blood vessels in fundus images are eliminated by a morphological ultimate operator. It will be in radius of sixteen pixels in flat disc forms. Using SD(Standard Deviation) of image is obtained from the following equation

$$I_4(a) = \frac{1}{N-1} \sum_{i \in Z(a)} \left(I_2(i) - \overline{I_4(a)} \right)^2$$

Set of all pixals in a subordinate window Z(a), mean of $I_2(i)$ is Z(x), the no. of pixels in Z(a) is N..Fig 3.5 shows the closed, threshold image

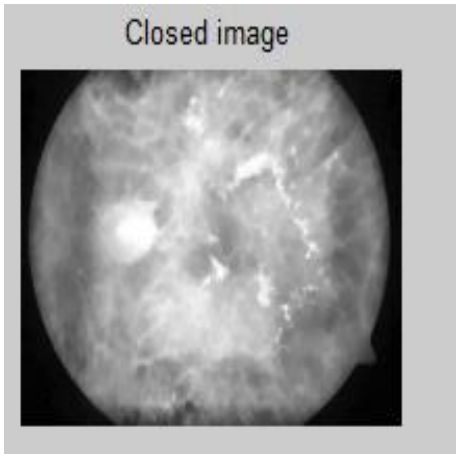

Fig 3.5 Closed and Thresholded Image

Morphological reformation is used in the next process. Now the marker image is obtained. For thresholding the pre-processed and optical disc eliminated image is compared with the original image. Here the difference between their intensity bands is calculated Fig 3.6 shows this closed and thresholded image. Fig 3.6 indicates the eroded and dilated Images.



Fig .3.6 Eroded and Dilated Images

Published By:
Blue Eyes Intelligence Engineering
and Sciences Publication (BEIESP)

Fig .3.7 Boundary Image

III. DISCUSSION &RESULT

Fifty images have been examined the use of MATLAB. The end outcome is overlapped images , the identified exudates are converted to overlapped images. The previously doubtful exudates areas have been clearly decorated and the exudates can be visibly discovered after the manner. This sort of presentation will help the health care persons to identify exudates more accurately and faster manner. Then they can easily identify the optic disc and removed.

To measure the accuracy of the set of rules Sensitivity and specificity had been selected on the pixel level. Not only does this assessment mechanism display how accurate our detection become, it also shows how misguided our detector may be. This pixel-based totally assessment considers 4 values, specifically TP, FP, FN,TN. Here True Positive indicates that some of exudates pixels detected accurately, FP indicates some of non-exudate pixels are wrongly identified, False Negative indicates exudate pixels not detected, True Negative indicates some of nonexudates pixels which were efficiently diagnosed as non-exudate pixels. From those portions, the responsiveness and specificity were computed the usage of the underneath formulation

Sensitivity = TRUE POSITIVE/TRUE POSITIVE+FALSE NEGATIVE

Specificity = TRUE NEGATIVE/TRUE NEGATIVE+FALSE POSITIVE

Here optic disc and exudates from DR patients are automatically located. The optic disc become detected and removed previous to the exudates identification due to the fact that each and every features areas are comparable. By using this technique the signs of diabetic retinopathy are detected easily and quickly by the ophthalmologist.

IV. CONCLUSION

In this researchwork a novel method is proposed to discover exudates using mathematical morphological methods and the gray scale image is used .Initially the image has high amount of noise extraordinary initial-processing techniquescan be carried out for noise quashing and improving attributestodraw regions displaying choppy assessment. The methodis absolutely mechanized and can be implemented without changing database of retinal images the parameters execution during the algorithm pixels used here is degraded potency.

REFERENCES

1. Basha, S.S., Prasad, K.S.(2008)"Automatic detection of hard exudates in diabetic retinopathy using morphological segmentation and fuzzy logic", Int. J. Comput. Sci. Netw. Secur., 8, (12), 211–218
2. M.C Gillaes,. and T.Y.Wong. (2007). "Management of diabetic retinopathy: A systematic review", "The Journal of the American Medical Association, JAWA, 298(8), 902–916".
3. Gonzalez R.C., Eddins S.L.: "Morphological reconstruction from digital image processing using MATLAB", "MATLAB Digest – Academic Edition".
4. H.F. Jelinek, C.Depardieu, ., Huang, W.,Cree, M.J.(2005) "Towards vessel characterisation in the vicinity of the optic disc in digital retinal images". "Image and Vision Computing Conf., 41–47".
5. V.V. Kumari, N.S.Narayanan.(2010) "Diabetic retinopathy – early detection using image processing techniques", Int. J. Comput. Sci. Eng., 357–361.
6. NayomiGeethanjaliRanamuka, RavindaGayan N. Meegama, (2013) "Detection of hard exudates from diabetic retinopathy images using fuzzy logic", "IET Image Processing ·, ISSN 1751-9659".
7. N.G. Ranamuka, R.G.N. Meegama (2013). "Detection of hard exudates from diabetic retinopathy images using fuzzy logic, Image Processing, IET 7(2), 121-130".
8. L.Xu, and S. Luo (2009). "Support vector machine based method for identifying hard exudates in retinal images, IEEE Youth Conference on Information Computing and Telecommunication".
9. Parivallal,R, Nagarajan,B, SathishKumar,R,(2012) "Zernike Feature Based Pattern Retrieval using Artificial Neural Network' Indian Journal of Engineering and Technology, Vol. 6 No 1 & 2".
10. Sathish Kumar, R, Nagarajan, B &Karthikamani, R (2016), "Security Enhancement for Automated Captcha Recognition System in Web Pages', Transylvanian Review, vol. XXIV, no. 10, 1640-1645."
11. Sathish Kumar, R, Nagarajan, B &Karthikamani, Dr. M. Gunasekaran, "Region-Based Object Extraction using Adaptive Neuro-Fuzzy Inference System Combined with Support Vector Machine, Asian Journal of Research in Social Sciences and Humanities, Vol. 7, No. 2, February 2017, pp. 412-427".

Published By:
Blue Eyes Intelligence Engineering and Sciences Publication (BEIESP)